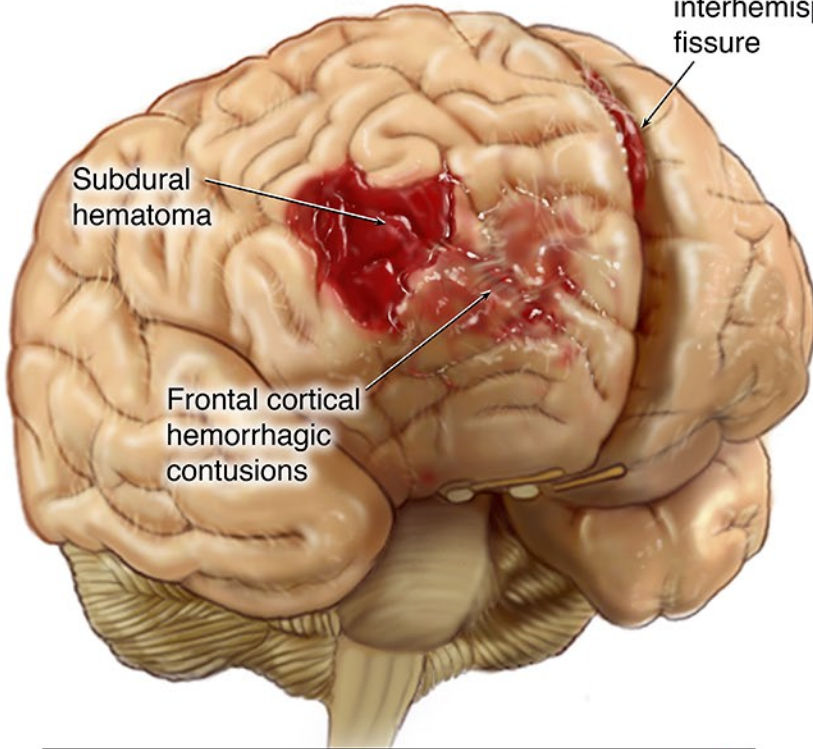


**Brain Injuries  
Right-Front View**

Subarachnoid hemorrhage within interhemispheric fissure

Subdural hematoma

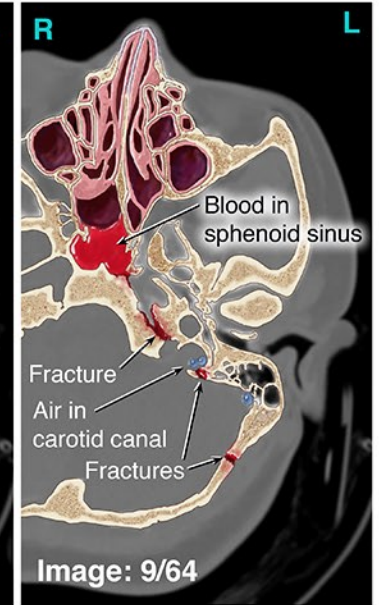
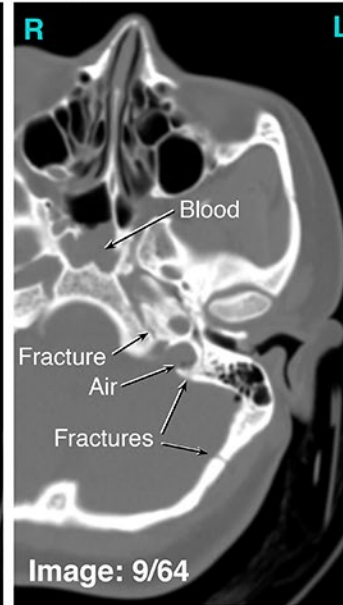
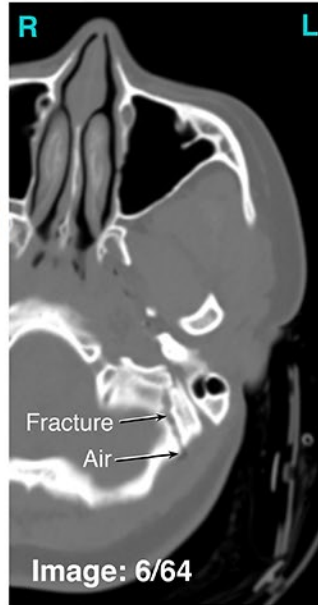
Frontal cortical hemorrhagic contusions



# Nicole Santiago

## Traumatic Skull and Brain Injuries

July 8, 2014 Axial CT



July 8, 2014 Axial CT

